


Digital planning and individual implants for secondary reconstruction of midfacial deformities: A pilot study

Paris Liokatis MD, DDS¹  | Yoana Malenova DDS¹ |
 Florian-Nepomuk Fegg MD, DDS¹ | Selgai Haidari MD, DDS¹ | Monika Probst MD² |
 Marko Boskov MD, DDS¹ | Carl-Peter Cornelius MD, DDS¹ |
 Matthias Troeltzsch MD, DDS¹ | Florian-Andreas Probst MD, DDS¹

¹Department of Oral and Maxillofacial Surgery and Facial Plastic Surgery, University Hospital, LMU Munich, Munich, Germany

²Department of Diagnostic and Interventional Neuroradiology, School of Medicine, Klinikum rechts der Isar, Technical University of Munich, Munich, Germany

Correspondence

Paris Liokatis, Department of Oral and Maxillofacial Surgery and Facial Plastic Surgery, University Hospital, LMU Munich, Lindwurmstr. 2a, 80337 Munich, Germany. Email: paris.liokatis@med.uni-muenchen.de

Funding information

Department of Oral and Maxillofacial Surgery and Facial Plastic Surgery, University Hospital

Abstract

Objective: To evaluate the feasibility and accuracy of implementing three-dimensional virtual surgical planning (VSP) and subsequent transfer by additive manufactured tools in the secondary reconstruction of residual post-traumatic deformities in the midface.

Methods: Patients after secondary reconstruction of post-traumatic midfacial deformities were included in this case series. The metrical deviation between the virtually planned and postoperative position of patient-specific implants (PSI) and bone segments was measured at corresponding reference points. Further information collected included demographic data, post-traumatic symptoms, and type of transfer tools.

Results: Eight consecutive patients were enrolled in the study. In five patients, VSP with subsequent manufacturing of combined predrilling/osteotomy guides and PSI was performed. In three patients, osteotomy guides, repositioning guides, and individually prebent plates were used following VSP. The median distances between the virtually planned and the postoperative position of the PSI were 2.01 mm ($n = 18$) compared to a median distance concerning the bone segments of 3.05 mm ($n = 12$). In patients where PSI were used, the median displacement of the bone segments was lower ($n = 7$, median 2.77 mm) than in the group with prebent plates ($n = 5$, 3.28 mm).

Conclusion: This study demonstrated the feasibility of VSP and transfer by additive manufactured tools for the secondary reconstruction of complex residual post-traumatic deformities in the midface. However, the median deviations observed in this case series were unexpectedly high. The use of navigational systems may further improve the level of accuracy.

This is an open access article under the terms of the Creative Commons Attribution-NonCommercial-NoDerivs License, which permits use and distribution in any medium, provided the original work is properly cited, the use is non-commercial and no modifications or adaptations are made.

© 2022 The Authors. *Laryngoscope Investigative Otolaryngology* published by Wiley Periodicals LLC on behalf of The Triological Society.

KEYWORDS

CAD/CAM, computer-assisted surgery, craniomaxillofacial trauma, patient-specific implants, virtual surgical planning

1 | INTRODUCTION

Secondary reconstruction of residual skeletal deformities is required on occasions after severe facial trauma when no treatment has been provided, or primary surgical treatment has resulted in unacceptable outcomes. Inaccurate reduction or remaining defects of the midface, especially of the zygomatic bone, the orbital walls, and the maxilla, can have functional and aesthetic consequences of varying degrees. Pronounced post-traumatic deformities may be associated with loss of sagittal projection, changes in vertical facial height, widening of the face, and facial asymmetry. In addition, impaired visual function, masticatory dysfunction, malocclusion, or temporomandibular joint disorders can occur.¹

Reconstructive surgery appears to benefit substantially from individualized virtual surgical planning (VSP), yielding more predictable outcomes than freehand techniques.¹ The advantages of computer-assisted planning, especially in complex surgery, are well documented in the literature.²⁻⁶ The application of surgical navigation systems supplementarily to these procedures is proposed to further improve outcomes.⁷⁻⁹ Intra-operative navigation, however, is a costly and sophisticated procedure due to the fact that it requires specialized technical equipment and trained personnel. Because of the aforementioned reasons the use of such equipment remains reserved to a few centers.

Many solutions have been proposed as alternatives to navigation systems.¹⁰⁻¹² The use of patient-specific implants (PSI) appears to be a promising option and has become increasingly important in recent years.¹³⁻¹⁶ Another practical approach is the use of conventional osteosynthesis plates, which are prebent on individual three-dimensional (3D) printed models.^{17,18}

So far, studies regarding secondary reconstruction of post-traumatic midfacial deformities use predominantly navigational systems.^{19,20} Implementing state-of-the-art computer-assisted planning, repositioning guides, and PSI for the same purpose is only sparsely discussed in case reports, with postoperative outcomes analyzed not thoroughly in metric dimensions.²¹ An exception is a study by Schouman et al.,²⁷ reporting on computer-assisted planning and application of PSI for the reduction and fixation of isolated zygoma fractures.

This is why the purpose of this study was to evaluate the feasibility and accuracy of implementing three-dimensional VSP and transferring it to surgery by additively manufactured tools in the secondary reconstruction of residual post-traumatic deformities in the midface, including the zygomatic, orbital, and maxillary region. The virtual planning technology is transferred into surgery either by means of repositioning guides together with preoperatively individually prebent conventional plates or by use of CAD/CAM fabricated osteotomy

guides and PSI. Intra-occlusal wafers were implemented in all cases with mobilization of edentulous parts.

2 | MATERIAL AND METHODS

2.1 | Study design

The study sample was obtained from a *consecutive* cohort of *patients* who underwent surgical treatment for formerly inadequately addressed fractures in the central and lateral midfacial region from 2013 to 2019 at the Department of Oral and Maxillofacial Surgery and Facial Plastic Surgery, University Hospital of LMU Munich, Germany. All subjects eligible for study inclusion were required to have undergone secondary osteotomies and osteosynthesis in the midface after VSP and transfer into surgery by CAD/CAM manufactured tools. The use of intra-operative navigation was a criterion for exclusion. Patients after isolated orbital wall or isolated Le Fort I fractures were also excluded from the study. Standards for reporting observational studies (STROBE guidelines) were followed.²² The institutional ethics committee approved the study protocol (approval number 19-783). Informed consent was obtained from all individual participants included in the study.

2.2 | VSP and additive manufacturing

High-resolution computed tomography scans of the facial skeleton with a slice thickness of 0.625 mm were performed. The DICOM data of the CT scan were imported into the ProPlan CMF software (DePuy Synthes Maxillofacial, Paoli, CA/Materialise, Leuven, Belgium). Image processing with conversion of DICOM datasets into 3D surface models was carried out. The soft tissues were removed with appropriate segmentation, and a 3D model of the craniofacial skeleton was generated. In case of repositioning of tooth-bearing maxillary segments, dental casts in occlusion were scanned and the 3D object generated was imported into the planning software and aligned with the rest of the skeleton.

VSP was performed in an interactive online meeting with the clinical engineers of the industrial partner. If the initial fracture lines could be identified, the 3D model was cut at these areas generating segments corresponding to the original post-traumatic fragments. However, due to the complexity of the fractures in our study, identifying the fracture lines was not always possible. In that case, the main osteotomy lines were defined concerning the existing deformity and aimed to mobilize the midface's related areas. For unilateral injury after setting a midsagittal symmetry plane, the unchanged shape of

the contralateral midface was mirrored and superimposed on the side with the post-traumatic deformity. For bilateral injury, symmetry in the three standard planes (axial, sagittal, coronal) was pursued. If the achieved symmetry or occlusion result after the reposition of the initial segments was inadequate, further osteotomy lines were planned to mobilize the specific parts of the segments leading to the disturbances. This resulted in many cases in a multisegmentation as the deformity correction necessitated the separate mobilization of adjacent regions to different directions. Especially regarding the repositioning of the maxilla, for the patients with an intact and not deformed lower jaw, the aim was to restore the pretraumatic occlusal pattern. If the mandible cannot be used as a reference, initially, the upper dental midline is corrected. After that, the maxilla's occlusal plane inclination (pitch) is adjusted to the desired angle. If the dental arch is asymmetric, further segmentation of the maxilla is performed, as described above. Subsequently, the maxilla is rotated (yaw/roll) to a balanced position.²³ After the asymmetry and the orientation of the maxilla have been corrected, the maxilla is moved anteroposteriorly and superoinferiorly to the desired position as determined by the cephalometric analysis and clinical measurements according to Segner/Hasund.^{24,25} In case 3 where the mandible was also post-traumatic deformed and a bilateral sagittal split was performed, the upper jaw was repositioned as described above. After that, the distal segment of the mandible is moved into maximal intercuspatation. Once the distal segment is in position, the proximal segments of the mandible are aligned.

Following the skeletal rearrangements, computer-aided design (CAD) of different transfer tools was performed, including 3D models,

interocclusal wafers, osteotomy and repositioning guides, combined predrilling/osteotomy guides, and PSI (Figure 1).

Depending on the case, either

- osteotomy guides and separate repositioning guides, together with individually prebent conventional plates (pre-bending was performed on 3D models) with intra-occlusal wafers or
- combined predrilling/osteotomy guides together with PSI and intra-occlusal wafers were used.

The plate design was individualized for each segment. Still, two fundamental principles were regarded: At least two screws prosegment were placed to achieve rotation stability. For a three-dimensionally accurate reposition and stable fixation, a three-point fixation of the main segments was pursued.

The CAD/CAM process was finally completed by additive manufacturing of the transfer tools (Figure 1). The PSI and the associated combined predrilling/osteotomy guides were manufactured from selective laser-melted titanium, whereas the osteotomy and repositioning guides were made from polyamide.

2.3 | Surgical technique

Individual surgical approaches were used in each case corresponding to the exposure required for the planned osteotomies, including intra-oral, palpebral, transconjunctival, and coronal incisions (Figure 1). Either piezosurgery instruments or a reciprocating saw were used

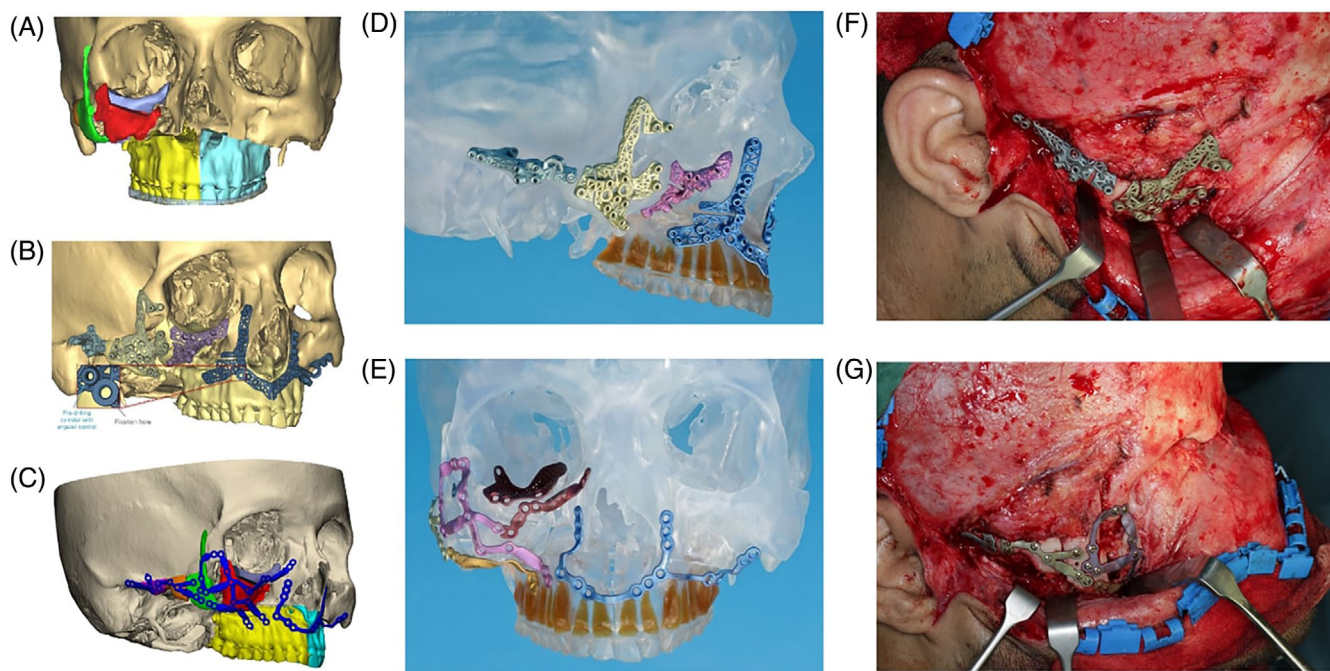


FIGURE 1 Computer-assisted workflow. (A) Virtual surgical planning with repositioning of bone segments, (B) CAD of combined predrilling/osteotomy guides, (C) CAD of PSI, (D) CAD/CAM-manufactured predrilling/osteotomy guides and (E) PSI, (F) intra-operative image showing the predrilling/osteotomy guides and (G) PSI in place

intra-operatively to carry out the osteotomies and re-osteotomies, respectively.

- In cases where no PSI were used, conventional osteosynthesis plates were individualized preoperatively by prebending on patient-specific 3D-printed bone models reflecting the planned segment positions. Osteotomy guides and separate repositioning guides were used for the cutting out and rearrangement of the bone segments. Finally, the prebent plates were employed for the fixation in the corrected new position.
- When PSI were employed, the associated combined predrilling/osteotomy guides were aligned to the bone surface and temporarily fixed with screws. Then, with this single guide, the designated holes for the PSI were predrilled by means of integrated drill sleeves and the planned osteotomies were carried out (Figure 1). Finally, the position of the PSI was transferred via the predrilled screw holes.

Computed tomography (CT) was performed postoperatively as a clinical routine.

2.4 | Study variables, data acquisition, and analysis

The study variables were collected by a retrospective chart review of medical history data, clinical findings, radiological findings, and surgical reports. The following variables were analyzed: demographic data, type of post-traumatic deformity and region of the midface regions involved (lateral midface including the zygomatic complex as well as the central midface including the inferior orbital rim and the maxilla), the delay between the initial trauma and the secondary correction, type and number of osteotomized segments, need for additional surgical procedures, type of surgical approach, type of additive manufactured tools used, type of osteosynthesis (individually prebent on the patient-specific 3D model or PSI), intra-operative need for additional manual bent plates, complications, and time of follow-up. In addition, the treatment plans were reviewed, and any modifications of the virtual plan were recorded.

For a metric assessment of the bone segment repositioning accuracy and the PSI positioning, the virtual surgical plan was compared to the postoperative CT. First, the DICOM data of the postoperative CT were imported into a medical image processing software (Mimics, Materialise). Image segmentation separated soft tissue (HU <300), bone tissue (HU 300–1000), and titanium (HU >1500). After image conversion to STL-files, the repositioned bone segments and the PSI were compared to the STL-files representing the predictive virtual planning in a CAD analyzing software (3-Matic, Materialise). For this purpose, the unaltered skull parts of the pre- and postoperative data sets, which were not affected by the surgery, were superimposed. Initially, a rough alignment of the models was performed using three anatomically corresponding landmarks. The landmarks were not standardized due to the different extent of the post-traumatic deformity in each case; they had to be, though, in the undeformed area of the face. Furthermore, a fine alignment was performed using a semi-automatic algorithm provided by the software using global registration.

The lateral midface and the central midface were each evaluated as separate units, even in the case of multisegmentation. Five evenly distributed reference points on the lateral surface of each virtual bone segment and each virtually designed PSI were determined. The landmarks were not standardized due to the different segment and PSI shapes but had to be possible to easily match on the corresponding postoperative segment or PSI. Especially for the tooth-bearing segments of the central midface, three of the five landmarks for each segment were assigned on teeth cusps (one anteriorly and one on each side) and two on the bone in the lateral cranial area of the segment. These reference points were selected by two independent examiners. 3D distances (Euclidean distances) between the corresponding reference points of the virtually planned segments and the PSI and the corresponding postoperative CT-based models were measured (3-Matic, Materialise). Color-coded difference images (heatmaps) visualized the localization of areas with high or low geometric deviations (Figure 2).

The reposition result was evaluated through reference points placed on the lateral surface of the bone based on the principle that the symmetry of the soft tissues requires a symmetrical underlining skeleton. The outcome regarding the soft tissues is affected by

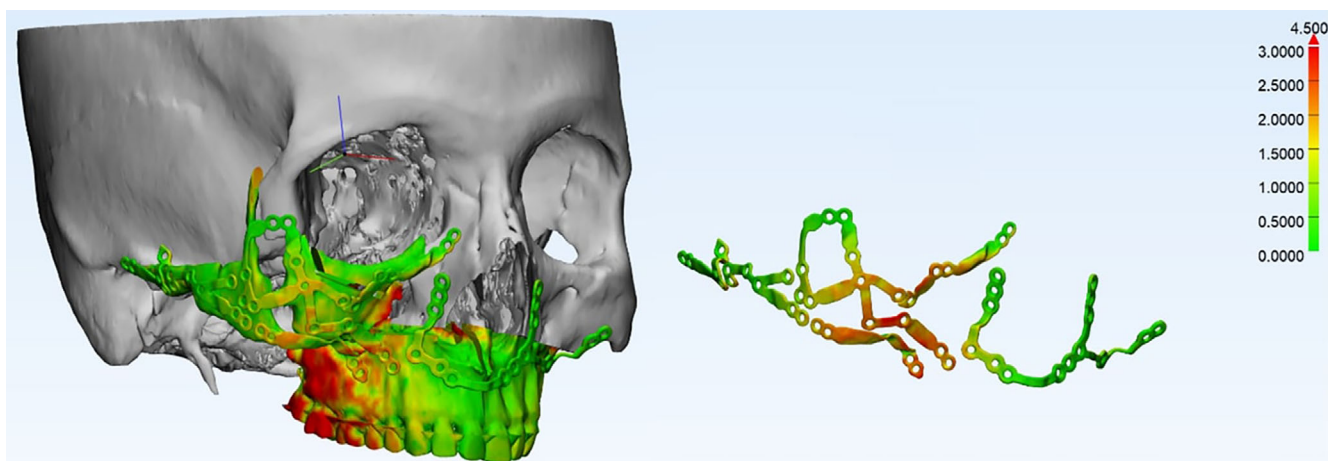
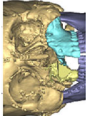
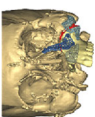
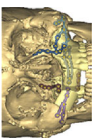
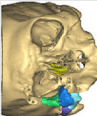
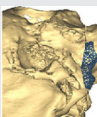
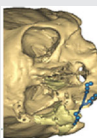

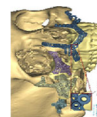
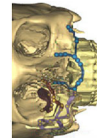
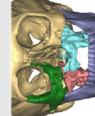
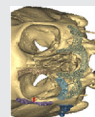
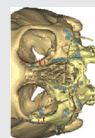
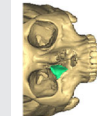
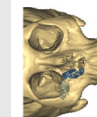
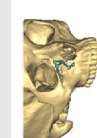
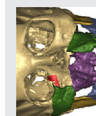
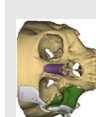
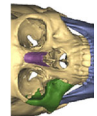
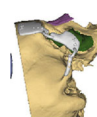

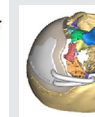


FIGURE 2 Color-coded difference images (heat maps) visualize the degree of geometric deviations for the bone segments and the PSI

TABLE 1 Procedures and materials associated with midface repositioning for each patient

Pt. no.	Age/sex	Delay after trauma (months)	Site	Type and number of osteotomized segments	Additional procedures	Osteosynthesis/ number of implants	Approach	VSP – bone segments	Surgical guides	PSI
1	21y/male	15	Maxilla	2	Fibula free graft	PSI	Endo-oral			
2	67y/male	68	Zygomatic bone	4	Reconstruction of orbital floor	PSI	Coronal			
3	29y/male	48	Zygomatic bone Maxilla	Zygomatic bone: 4 Maxilla: 2	Bilateral sagittal split of the mandible	PSI	Coronal, endo-oral, palpebral			
4	38y/female	84	Zygomatic bone Maxilla	Zygomatic bone: 2 Maxilla: 2	Bilateral reconstruction of the orbital floor and mandible	PSI	Coronal, endo-oral, palpebral			
5	31y/male	6	Inferior orbital rim fracture	1		PSI	Transconjunctival, endo-oral			
6	35y/male	42	Zygomatic bone Maxilla	Zygomatic bone: 1 Maxilla: 2	Reconstruction of the orbital floor and mandible	Prebent plates	Preauricular, palpebral, endo-oral			-
7	29y/female	35	Zygomatic bone	Zygomatic bone: 1	Reposition of the nasal skeleton and mandible	Prebent plates	Coronal, endo-oral, palpebral			-
8	36y/male	36	Zygomatic bone Maxilla	Zygomatic bone: 1 Maxilla: 1		Prebent plates	Coronal, endo-oral, palpebral			-

additional parameters such as defects, scar contractures, nerve palsies, and so on and was not evaluated in this study.

2.5 | Statistical analysis

Statistical analysis was performed by Excel (Microsoft, Redmond, WA) and SPSS 25 (SPSS Inc., Chicago, IL). The data were tested for normal distribution using the Kolmogorov–Smirnov test and Shapiro–Wilk test and were not normally distributed. Therefore, the median and range of the geometric deviations were calculated. Additionally, the reliability of the measurements of the two examiners was tested with the intraclass correlation (ICC) analysis separately for the bone segments and the PSI.

3 | RESULTS

Eight consecutive patients (6 men, 2 women) were enrolled between October 2013 and April 2019 in the study. The average age was 35.7 years (range 21–67 years). The delay between the initial trauma

and surgery was 43 months on average (range: 7 months to 7 years). Three patients (cases 3, 5, and 7) had not undergone any prior surgical treatment in the midface area.

The prominent post-traumatic deformity in the cohort was facial asymmetry resulting from loss of the facial projection. The second most common complaint made was malocclusion, often together with the loss of teeth. Patient 5 also suffered from an ipsilateral ectropion. Other complaints were scars and facial synkinesis.

Five patients received VSP followed by PSI fabrication ($n = 19$), and three patients underwent VSP followed by the use of individually prebent plates. At patient 1, a Le Fort I osteotomy and maxillary reconstruction with a fibula-free flap was performed. Patient 2 underwent a multisegmentation of the zygomatic complex into four segments. Patients 3 and 4 received multisegmentation of the dislocated zygomatic bone and maxilla. In patient 5, re-osteotomies and repositioning of the inferior orbital rim were performed. Patient 6 was treated with a combined osteotomy of the zygomatic bone and maxilla. Patient 7 received a reposition of the zygomatic complex in one segment.

For the reposition of the maxillary segments, interocclusal wafers with mandibulo-maxillary fixation (MMF) were additionally employed. Major complications were not reported. The treatment plans were reviewed, and

TABLE 2 Variables examined for each patient

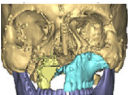
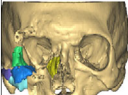
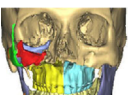
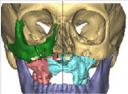
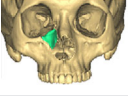


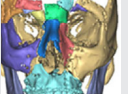
Pt. no.	VSP – bone segments	Post-traumatic deformity	Regions involved	Type of osteosynthesis	Intra-operative need for additional manual bent plates	Time of follow-up (months)	Complications	Need for revision/further procedures
1		Facial asymmetry, malocclusion, bone loss	Central midface	PSI	No	37	-	Plate removal
2		Facial asymmetry, loss of projection	Lateral midface	PSI	No	46	-	-
3		Facial asymmetry, loss of projection, malocclusion	Central and lateral midface	PSI	No	44	-	-
4		Facial asymmetry, malocclusion	Central and lateral midface	PSI	Yes	21	-	Dental implants
5		Ectropion, facial asymmetry	Central midface	PSI	No	13	-	-
6		Loss of projection, malocclusion	Central and lateral midface	Individually prebent plates	Yes	79	-	-
7		Loss of facial projection	Lateral midface	Individually prebent plates	No	63	-	Plate removal
8		Loss of projection, malocclusion	Central and lateral midface	Individually prebent plates	No	55	-	-

TABLE 3 Single deviations between the virtually planned and postoperative position of the bone segments and the PSI

Pat.	Region of the midface involved	PSI	Median deviation bone segment (mm)			Median deviation PSI (mm)
			As a whole	Occlusal part	Non-occlusal part	
1	Central	Yes	3.74	2.03	4.97	2.37/4.86/2.17/3.86
2	Lateral	Yes	2.93			1.12
3	Lateral	Yes	2.22			1.72/1.31/2.39/2.36/2.54
	Central	Yes	2.35	1.62	4.04	1.3
4	Lateral	Yes	1.68			1.10/1.84/5.61/2.95
	Central	Yes	2.77	1.07	3.98	1.59/0.92
5	Central	Yes	3.48			0.95
6	Lateral	No	4.79			
	Central	No	3.16	2.11	5.51	
7	Lateral	No	2.87			
8	Lateral	No	6.06			
	Central	No	3.28	3.28	3.79	

Note: In some cases, more than one PSI was placed.

all planned procedures were implemented as intended, without major intra-operative modifications. One of the 19 PSI was placed in a different location than planned (case 1), and this PSI was excluded from further statistical analysis. Additional conventional plates were not used in any of the cases. Two out of eight patients wished and had their plates removed (15 and 24 months after the main operation) due to a subjective feeling of pressure in the midface. For these patients, no operation-related complications were reported. Furthermore, no bone sequestration was observed in any cases. The associated procedures and main study variables collected for each patient are summarized in Tables 1 and 2.

General superimposition accuracy between unchanged parts of the pre- and postoperative skull models showed a mean error of 0.026 mm. The intraclass correlation (ICC) value was 0.824 for the bone segments and 0.946 for the PSI, indicating good reliability of the measurements between the two examiners, according to Koo and Li.²⁶

The median distances between the virtually planned and the postoperative position of the PSI were 2.01 mm ($n = 18$, range 0.92–5.61 mm) compared to a median distance between the planned and postoperative position of all bone segments of 3.05 mm ($n = 12$, range 1.68–6.06 mm) (Figure 3). The individual deviations between the planned and postoperative position of each PSI and each bone segment are displayed in Table 3.

In the patients where PSI were used, the median displacement of the total number of bone segments was lower ($n = 7$, median 2.77 mm, range 1.68–3.74 mm) than in the group with prebent plates ($n = 5$, 3.28 mm, range 2.87–6.06 mm) (Figure 4).

The median distance between the virtually planned and the postoperative position of the bone segments was 2.90 mm ($n = 6$, range 1.68–6.06 mm) for the lateral midface compared to 3.22 mm ($n = 6$, range 2.35–3.74 mm) for the central midface (Figure 5).

For the tooth-bearing segments of the central midface (cases 1, 3, 4, 6, 8), each segment's median displacement was also analyzed separately for the position of the dental arch and the rest of the segment (Table 3). The dental arch showed a median displacement of 2.03 mm

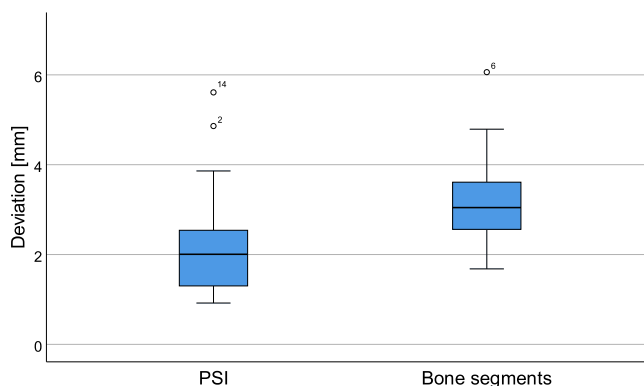


FIGURE 3 Median distance between the virtually planned and the postoperative position of the PSI themselves (left; $n = 18$, median 2.01 mm, range 0.92–5.61 mm) and median distance of the bone segments (right; $n = 12$, median 3.05 mm ($n = 12$, range 1.68–6.06 mm)

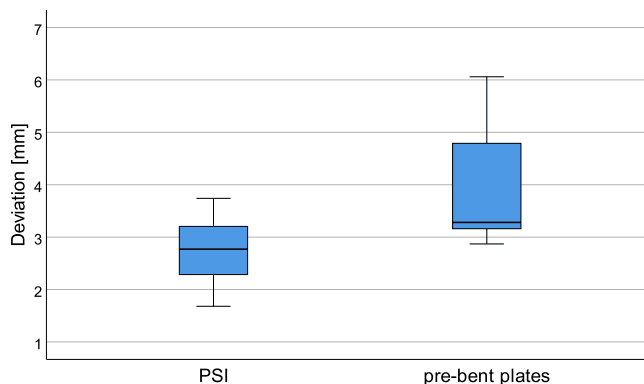


FIGURE 4 Median distances between the virtually planned and the postoperative position of all bone segments in the group where PSI were applied (left; $n = 7$, median 2.77 mm, range 1.68–3.74 mm) and in the group without using PSI (right; $n = 5$, median 3.28 mm, range 2.87–6.06 mm)

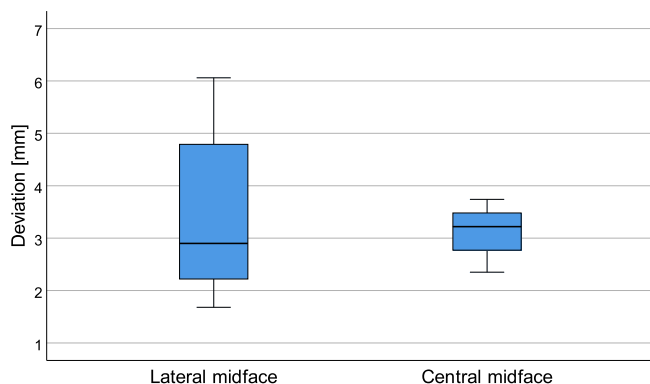


FIGURE 5 Median distances between the virtually planned and the postoperative position of the lateral midface segments (left: $n = 6$, median 2.90 mm, range 1.68–6.06 mm) and the central midface segments (right: $n = 6$, median 3.22 mm, range 2.35–3.74 mm)

($n = 5$, 1.07–3.28 mm), whereas the cranial part of the segments was in median 4.04 mm ($n = 5$, 3.79–5.51 mm) displaced.

4 | DISCUSSION

Secondary correction of craniomaxillofacial post-traumatic deformities is a challenging procedure that requires a good understanding of the three-dimensional anatomy of the facial skeleton. One advantage is that there is a sufficient time frame for thorough planning and preparation in these secondary procedures, which allows for computer-aided planning and additive manufacturing. This time frame makes delays between the planning process and the delivery of the CAD/CAM-manufactured surgical tools a negligible factor. The virtual planning technology combined with PSI or individually prebent plates does not require additional equipment and training and is therefore readily available. However, the cost of using digital planning and custom implants is in the mid to high four figures depending on the complexity of the case. For this reason researching and presenting the performance of these methods is necessary. Alternatively, the use of conventional plates prebent on patient-specific models with or without repositioning aids instead of PSI is an option to reduce costs and still be able to implement plan changes at short notice.

This study aimed to evaluate the feasibility and accuracy of three-dimensional VSP and transfer by additive manufactured tools of secondary reconstruction of residual post-traumatic deformities in the midface. All operations were carried out after prior virtual operation planning, albeit minor adjustments were necessary in some cases.

The present pilot study evaluates the treatment of complex residual midface deformities either by employing PSI together with combined predrilling/osteotomy guides or by using individually prebent conventional plates (prebending on 3D models) together with osteotomy guides and separate repositioning guides. All surgeries were performed without intra-operative navigation. Both surgical techniques showed practical feasibility. In patients where PSI were used, the median displacement of bone segments was lower than in the group

in which osteosynthesis was performed with prebent plates. The metrically assessed accuracy of the bone segment repositioning (median 3.05 mm, range 1.68–6.06 mm) and the PSI positioning (median 2.01 mm, range 0.92–5.61 mm) was unexpectedly high in our series. Besides, procedures involving the central midface showed a trend to an increased deviation compared to the lateral midface, while within the maxillary segments, the deviation in the region of the dental arch was lower (median 2.03 mm, 1.07–3.28 mm) than the one in the cranial area of the bone segments (median 4.04 mm, 3.79–5.51 mm). However, these metrical results must be regarded with caution due to the small group size and heterogeneous fracture patterns.

Schouman et al.²⁷ first proposed the use of PSI and surgical guides for the accurate execution of re-osteotomies in post-traumatic midface deformities. The subsequent reposition of the zygomatic bone achieved an excellent accuracy of 0.2 mm (range 0.05–0.38 mm).²⁷ In analogy to five patients in our study, PSI in combination with predrilling/osteotomy guides made from titanium were also used in this study from Schouman et al. The reposition accuracy of the zygomatic bones was based in the study from Schouman et al.²⁷ on measuring the distance from each point of the postoperative bone-model to the nearest point in the planning-model using an algorithm provided by the planning software. However, this method can severely underestimate the total geometric displacement, as two points closest to each other do not necessarily match anatomically.²⁸ In our study, far more complex corrections of the midface with single or multisegment osteotomies took place in combination with Le Fort I osteotomies and, in one case, combined a Le Fort I osteotomy with a virtually planned free fibula-flap transfer. The comparatively higher deviation between planned and resulting positions in our study compared to Schouman et al.²⁷ is explainable by differences in the method of evaluation as well as by the complexity of the deformities, osteotomies and surgical procedures.

Although greater skeletal deviations in the midface with maximum outliers of up to 6 mm may not have clinical relevance in terms of aesthetics, occlusal displacement even in a millimeter range could lead to functional problems. To evaluate the repositioning accuracy in the dental arch area, computer-assisted surgical techniques employing PSI and associated surgical guides have also been reported and evaluated in mandibular reconstruction²⁹ and orthognathic surgery^{6,30–34} using landmark methods similar to the method implemented in our study. Based on the pre- and postoperative evaluation of five occlusal landmarks, high accuracy in maxillary positioning by CAD/CAM fabricated PSI and surgical guides for predrilling and osteotomies was reported with an average deviation of 0.39 mm and a maximum error of 2.02 mm.⁶ Using PSI and surgical guides, lower discrepancies between the planned and the final positions of the maxilla were seen compared to VSP and subsequent transfer with customized interocclusal splints, especially in anterior/posterior positioning (average for the PSI group: 0.39 mm, range 0.04–0.83 mm vs. average of the interocclusal splint group: 1.42 mm, range 0.47–3.04).³⁴

In our case series, the deviation of the central midface segments was analyzed separately for the dental arch and the rest of the bone segment, with the dental arch showing a lower deviation (2.03 mm,

1.07–3.28 mm) compared to the cranial areas of the bone segments (4.04 mm, 3.79–5.51 mm). The median deviation of 2.03 mm for the dental arch found in our study is significantly higher than the one previously reported in orthognathic surgery.^{6,34} However, in orthognathic patients, the performed osteotomies are standardized without multisegmentation, the patients are adequately toothed, the tissues are not scarred and without defects and the movements of the mobilized segments are more delicate. All these factors could decrease the repositioning inaccuracy of post-traumatic deformities. The increased deviation between planned and final positions in our study can be attributed to the increased complexity of our cases with multisegmentation of the maxilla. Moreover, in most cases, both the zygoma and maxilla were repositioned in the same procedure, which introduces an additional factor for increased inaccuracy compared to orthognathic studies.^{6,34} Furthermore, the landmark-based evaluation method implemented in this study has limitations and may overestimate the measured deviation.³⁴

The increased inaccuracy of the dental arch reposition found in our study raises considerations about the adequacy of the transfer tools used (PSI and intra-occlusal wafers) without intra-operative navigation when a multisegmentation of the maxilla or a simultaneous mobilization of the zygoma is planned. Moreover, the need for additional orthodontic treatment after such complex repositions should also be discussed with the patient.

The accuracy of computer-assisted surgery depends largely on how accurately the virtual planning is transferred into the operation. For this purpose, different CAD/CAM-manufactured tools such as various surgical guides and PSI plus surgical navigation can be employed. When using surgical templates, they must be positioned as closely as possible as in the virtual planning. To ensure prompt and reproducible positioning of the guides, prominent landmarks should be used to assist in positioning. Temporary fixation screws help to secure the correct guide position. The application of the guides often requires an extended degloving of the facial skeleton. Potential negative consequences are an increased risk for bleeding, swelling, nerve lesions, and soft tissue sagging.

So far, only a qualitative evaluation of the achieved positioning accuracy using the repositioning guides has been reported.^{11,12} Other principal sources of error in computer-assisted surgery involve different aspects in imaging and image processing.³⁵

The accuracy could be improved by using navigational systems. Surgical navigation is considered a helpful method for reproducing digitally planned midface osteotomies, especially for the zygomatic area.³⁶ Some studies, mainly case reports or case series, have presented the implementations of this technology with or without the additional use of patient-specific plates. Only a few of them examined the achieved accuracy.^{5,37,38} Surgical navigation presents additional difficulties due to lack, often, of accurate anatomic landmarks in the midface area,³⁹ mainly due to severe trauma and primary operations. The technology requires trained operators, expensive equipment, and most likely more operating time. Because a navigation and calibration error of 1–2 mm can commonly be assumed,^{40–43} a deviation of up to 2 mm may be considered excellent for computer-assisted surgery. Surgical navigation may be employed in two ways. It could be used for the exact positioning of

surgical guides for cutting and drilling. The guides must be provided with navigational landmarks for this purpose, as is established, for example, in orbital wall reconstruction.⁴⁴ This then enables the correct positioning of the bone segments and the implants. Additionally, navigation-guided positioning of bone segments can be used, either via fiducial-based paired-point transformation or by surface contour matching.³⁶

There are some limitations to the present study design that need to be discussed. First of all, this is a retrospective study with the associated known drawbacks. Additionally, the sample size is relatively small, and the cohort exhibits quite different types of deformities. Furthermore, because landmark-based evaluation might have limitations in terms of repeatability, reproducibility, and overestimation of the inaccuracy of the reposition outcome, an algorithm independent of landmark identification was proposed in the study by Ruckschloss et al.³⁴ Moreover, the outcome's evaluation was based mainly on a computer analysis of the achieved repositioning accuracy and not on a long-time clinical assessment of the patients.

Future prospective surveys should consider larger sample sizes and more homogenous subgroups with similar defect types to better estimate the accuracy, cost–benefit ratio, and difficulties of the demonstrated computer-assisted approach. Moreover, different control groups, including conventional surgery and the use of navigational systems, are preferable. Because post-traumatic deformities are not too frequently occurring in everyday clinical practice, even in larger centers, multicenter studies will be required. The data pool obtained in our study might be used as a suitable basis for calculating the sample size.

5 | CONCLUSION

In conclusion, this study demonstrated the practical feasibility of three-dimensional virtual surgical planning and transfer by additive manufactured tools of secondary reconstruction of complex residual post-traumatic deformities in the midface. However, the repositioning inaccuracy reported in this study is unexpectedly high and the use of navigational systems may further improve the level of accuracy.

ACKNOWLEDGMENT

The work was supported by the Department of Oral and Maxillofacial Surgery and Facial Plastic Surgery, University Hospital, Munich, Germany.

CONFLICT OF INTEREST

The authors declare that there is no conflict of interest that could be perceived as prejudicing the impartiality of the research reported.

ORCID

Paris Liokatis  <https://orcid.org/0000-0002-6109-638X>

REFERENCES

- Amundson M, Newman M, Cheng A, Khatib B, Cuddy K, Patel A. Three-dimensional computer-assisted surgical planning, manufacturing, intraoperative navigation, and computed tomography in maxillofacial

- trauma. *Atlas Oral Maxillofac Surg Clin North Am.* 2020;28(2):119-127. doi:10.1016/j.cxom.2020.05.006
2. Steinbacher DM. Three-dimensional analysis and surgical planning in craniomaxillofacial surgery. *J Oral Maxillofac Surg.* 2015;73:S40-S56. doi:10.1016/j.joms.2015.04.038
 3. Adolphs N, Haberl EJ, Liu W, Keeve E, Menneking H, Hoffmeister B. Virtual planning for craniomaxillofacial surgery—7 years of experience. *J Craniomaxillofac Surg.* 2014;42(5):e289-e295. doi:10.1016/j.jcms.2013.10.008
 4. Mertens C, Lowenheim H, Hoffmann J. Image data based reconstruction of the midface using a patient-specific implant in combination with a vascularized osteomyocutaneous scapular flap. *J Craniomaxillofac Surg.* 2013;41(3):219-225. doi:10.1016/j.jcms.2012.09.003
 5. Scolozzi P. Maxillofacial reconstruction using polyetheretherketone patient-specific implants by “mirroring” computational planning. *Aesthetic Plast Surg.* 2012;36(3):660-665. doi:10.1007/s00266-011-9853-2
 6. Heufelder M, Wilde F, Pietzka S, et al. Clinical accuracy of waferless maxillary positioning using customized surgical guides and patient specific osteosynthesis in bimaxillary orthognathic surgery. *J Craniomaxillofac Surg.* 2017;45(9):1578-1585. doi:10.1016/j.jcms.2017.06.027
 7. Watzinger F, Wanschitz F, Wagner A, et al. Computer-aided navigation in secondary reconstruction of post-traumatic deformities of the zygoma. *J Craniomaxillofac Surg.* 1997;25(4):198-202. doi:10.1016/s1010-5182(97)80076-5
 8. Klug C, Schicho K, Ploder O, et al. Point-to-point computer-assisted navigation for precise transfer of planned zygoma osteotomies from the stereolithographic model into reality. *J Oral Maxillofac Surg.* 2006;64(3):550-559. doi:10.1016/j.joms.2005.11.024
 9. Marmulla R, Niederdellmann H. Computer-assisted bone segment navigation. *J Craniomaxillofac Surg.* 1998;26(6):347-359. doi:10.1016/s1010-5182(98)80067-x
 10. Xia JJ, Gateno J, Teichgraber JF. A new paradigm for complex midface reconstruction: a reversed approach. *J Oral Maxillofac Surg.* 2009;67(3):693-703. doi:10.1016/j.joms.2008.08.024
 11. Herlin C, Koppe M, Beziat JL, Gleizal A. Rapid prototyping in craniofacial surgery: using a positioning guide after zygomatic osteotomy—a case report. *J Craniomaxillofac Surg.* 2011;39(5):376-379. doi:10.1016/j.jcms.2010.07.003
 12. Murray DJ, Edwards G, Mainprize JG, Antonyshyn O. Optimizing craniofacial osteotomies: applications of haptic and rapid prototyping technology. *J Oral Maxillofac Surg.* 2008;66(8):1766-1772. doi:10.1016/j.joms.2007.08.031
 13. Cornelius CP, Smolka W, Giessler GA, Wilde F, Probst FA. Patient-specific reconstruction plates are the missing link in computer-assisted mandibular reconstruction: a showcase for technical description. *J Craniomaxillofac Surg.* 2015;43(5):624-629. doi:10.1016/j.jcms.2015.02.016
 14. Mazzoni S, Bianchi A, Schiariti G, Badiali G, Marchetti C. Computer-aided design and computer-aided manufacturing cutting guides and customized titanium plates are useful in upper maxilla waferless repositioning. *J Oral Maxillofac Surg.* 2015;73(4):701-707. doi:10.1016/j.joms.2014.10.028
 15. Schepers RH, Raghoebar GM, Vissink A, et al. Accuracy of fibula reconstruction using patient-specific CAD/CAM reconstruction plates and dental implants: a new modality for functional reconstruction of mandibular defects. *J Craniomaxillofac Surg.* 2015;43(5):649-657. doi:10.1016/j.jcms.2015.03.015
 16. Cornelius CP, Mast G, Ehrenfeld M. Computer-assisted surgical planning and execution-models, cutting and drill guides, positioning aides, and patient specific implants. In: Ehrenfeld M, Futran ND, Manson PN, Prein J, eds. *Advanced Craniomaxillofacial Surgery-Tumor, Corrective Bone Surgery and Trauma.* Thieme Publishers; 2020:635-676.
 17. Fowell C, Edmondson S, Martin T, Praveen P. Rapid prototyping and patient-specific pre-contoured reconstruction plate for comminuted fractures of the mandible. *Br J Oral Maxillofac Surg.* 2015;53(10):1035-1037. doi:10.1016/j.bjoms.2015.06.018
 18. Kozakiewicz M, Elgalal M, Loba P, et al. Clinical application of 3D pre-bent titanium implants for orbital floor fractures. *J Craniomaxillofac Surg.* 2009;37(4):229-234. doi:10.1016/j.jcms.2008.11.009
 19. Castro-Nunez J, Van Sickels JE. Secondary reconstruction of maxillofacial trauma. *Curr Opin Otolaryngol Head Neck Surg.* 2017;25(4):320-325. doi:10.1097/MOO.0000000000000368
 20. Gellrich NC, Schramm A, Hammer B, et al. Computer-assisted secondary reconstruction of unilateral posttraumatic orbital deformity. *Plast Reconstr Surg.* 2002;110(6):1417-1429. doi:10.1097/01.PRS.0000029807.35391.E5
 21. Patel N, Kim B, Zaid W. Use of virtual surgical planning for simultaneous maxillofacial osteotomies and custom polyetheretherketone implant in secondary orbito-frontal reconstruction: importance of restoring orbital volume. *J Craniofac Surg.* 2017;28(2):387-390. doi:10.1097/SCS.00000000000003313
 22. von Elm E, Altman DG, Egger M, et al. The strengthening the reporting of observational studies in epidemiology (STROBE) statement: guidelines for reporting observational studies. *Lancet.* 2007;370(9596):1453-1457. doi:10.1016/S0140-6736(07)61602-X
 23. Elnagar MH, Aronovich S, Kusnoto B. Digital workflow for combined orthodontics and orthognathic surgery. *Oral Maxillofac Surg Clin North Am.* 2020;32(1):1-14. doi:10.1016/j.coms.2019.08.004
 24. Segner D, Hasund A. *Individualisierte Kephalmetrie. 4. Auflage Edn. Hansa-Dont, c/o Kfo.Abt. UKE.* Fachbuchverlag; 1991.
 25. Swennen GR, Schutyser F, Barth EL, De Groeve P, De Mey A. A new method of 3-D cephalometry part I: the anatomic Cartesian 3-D reference system. *J Craniofac Surg.* 2006;17(2):314-325. doi:10.1097/00001665-200603000-00019
 26. Koo TK, Li MY. A guideline of selecting and reporting intraclass correlation coefficients for reliability research. *J Chiropr Med.* 2016;15(2):155-163. doi:10.1016/j.jcm.2016.02.012
 27. Schouman T, Murcier G, Goudot P. The key to accuracy of zygoma repositioning: suitability of the SynpliciTi customized guide-plates. *J Craniomaxillofac Surg.* 2015;43(10):1942-1947. doi:10.1016/j.jcms.2014.12.014
 28. van Eijnatten M, van Dijk R, Dobbe J, Streekstra G, Koivisto J, Wolff J. CT image segmentation methods for bone used in medical additive manufacturing. *Med Eng Phys.* 2018;51:6-16. doi:10.1016/j.medengphy.2017.10.008
 29. Schouman T, Bertolus C, Chaine C, Ceccaldi J, Goudot P. Surgery guided by customized devices: reconstruction with a free fibula flap. *Rev Stomatol Chir Maxillofac Chir Orale.* 2014;115(1):28-36. doi:10.1016/j.revsto.2013.09.002
 30. Bai S, Bo B, Bi Y, et al. CAD/CAM surface templates as an alternative to the intermediate wafer in orthognathic surgery. *Oral Surg Oral Med Oral Pathol Oral Radiol Endod.* 2010;110(5):e1-e7. doi:10.1016/j.tripleo.2010.05.052
 31. Bai S, Shang H, Liu Y, Zhao J, Zhao Y. Computer-aided design and computer-aided manufacturing locating guides accompanied with prebent titanium plates in orthognathic surgery. *J Oral Maxillofac Surg.* 2012;70(10):2419-2426. doi:10.1016/j.joms.2011.12.017
 32. Olszewski R, Tranduy K, Reyhler H. Innovative procedure for computer-assisted genioplasty: three-dimensional cephalometry, rapid-prototyping model and surgical splint. *Int J Oral Maxillofac Surg.* 2010;39(7):721-724. doi:10.1016/j.ijom.2010.03.018
 33. Polley JW, Figueroa AA. Orthognathic positioning system: intraoperative system to transfer virtual surgical plan to operating field during orthognathic surgery. *J Oral Maxillofac Surg.* 2013;71(5):911-920. doi:10.1016/j.joms.2012.11.004
 34. Ruckschloss T, Ristow O, Muller M, et al. Accuracy of patient-specific implants and additive-manufactured surgical splints in orthognathic surgery—a three-dimensional retrospective study.

- J Craniomaxillofac Surg.* 2019;47(6):847-853. doi:10.1016/j.jcms.2019.02.011
35. van Eijnatten M, Koivisto J, Karhu K, Forouzanfar T, Wolff J. The impact of manual threshold selection in medical additive manufacturing. *Int J Comput Assist Radiol Surg.* 2017;12(4):607-615. doi:10.1007/s11548-016-1490-4
 36. He Y, Zhang Y, Yu GY, et al. Expert consensus on navigation-guided unilateral delayed zygomatic fracture reconstruction techniques. *Chin J Dent Res.* 2020;23(1):45-50. doi:10.3290/j.cjdr.a44335
 37. Chen X, Lin Y, Wang C, Shen G, Zhang S, Wang X. A surgical navigation system for oral and maxillofacial surgery and its application in the treatment of old zygomatic fractures. *Int J Med Robot.* 2011;7(1):42-50. doi:10.1002/rcs.367
 38. Yu H, Shen G, Wang X, Zhang S. Navigation-guided reduction and orbital floor reconstruction in the treatment of zygomatic-orbital-maxillary complex fractures. *J Oral Maxillofac Surg.* 2010;68(1):28-34. doi:10.1016/j.joms.2009.07.058
 39. He Y, Zhang Y, An JG, Gong X, Feng ZQ, Guo CB. Zygomatic surface marker-assisted surgical navigation: a new computer-assisted navigation method for accurate treatment of delayed zygomatic fractures. *J Oral Maxillofac Surg.* 2013;71(12):2101-2114. doi:10.1016/j.joms.2013.07.003
 40. Dubois L, Schreurs R, Jansen J, et al. Predictability in orbital reconstruction: a human cadaver study. Part II: navigation-assisted orbital reconstruction. *J Craniomaxillofac Surg.* 2015;43(10):2042-2049. doi:10.1016/j.jcms.2015.07.020
 41. Schreurs R, Dubois L, Becking AG, Maal TJJ. Implant-oriented navigation in orbital reconstruction. Part 1: technique and accuracy study. *Int J Oral Maxillofac Surg.* 2018;47(3):395-402. doi:10.1016/j.ijom.2017.09.009
 42. Schreurs R, Dubois L, Ho J, et al. Implant-oriented navigation in orbital reconstruction part II: preclinical cadaver study. *Int J Oral Maxillofac Surg.* 2020;49(5):678-685. doi:10.1016/j.ijom.2019.09.009
 43. Azarmehr I, Stokbro K, Bell RB, Thygesen T. Contemporary techniques in orbital reconstruction: a review of the literature and report of a case combining surgical navigation, computer-aided surgical simulation, and a patient-specific implant. *J Oral Maxillofac Surg.* 2020;78(4):594-609. doi:10.1016/j.joms.2019.11.005
 44. Rana M, Chui CH, Wagner M, Zimmerer R, Rana M, Gellrich NC. Increasing the accuracy of orbital reconstruction with selective laser-melted patient-specific implants combined with intraoperative navigation. *J Oral Maxillofac Surg.* 2015;73(6):1113-1118. doi:10.1016/j.joms.2015.02.014

How to cite this article: Liokatis P, Malenova Y, Fegg F-N, et al. Digital planning and individual implants for secondary reconstruction of midfacial deformities: A pilot study. *Laryngoscope Investigative Otolaryngology.* 2022;7(2):369-379. doi:10.1002/lio2.753