

## FOOT &amp; ANKLE

# A systematic review of studies on the diagnostics and classification system used in surgically treated, acute, isolated, unstable syndesmotic injury: a plea for uniform definition of syndesmotic injuries

Fabian Tobias Spindler<sup>ID</sup>, Wolfgang Böcker, Hans Polzer<sup>ID</sup> and Sebastian Felix Baumbach<sup>ID</sup>

Department of Orthopaedics and Trauma Surgery, Musculoskeletal University Center Munich (MUM), University Hospital, LMU Munich, Munich, Germany

Correspondence should be addressed to H Polzer Email [Hans.Polzer@med.uni-muenchen.de](mailto:Hans.Polzer@med.uni-muenchen.de)

- **Objective:** To this day, diagnostic standards and uniform definition for acute, isolated syndesmotic injuries are missing. The aim of the current study was to conduct a systematic review of the classification systems and diagnostics currently applied and to propose a best evidence diagnostic approach.
- **Methods:** Medline (PubMed), Scopus, Cochrane Central Register of Controlled Trials, and Embase were searched from inception to June 5, 2022, for studies reporting the outcome of surgically treated acute, isolated syndesmotic injuries. First, all classifications used in the eligible studies were identified and illustrated according to the individual syndesmotic structures injured. Second, the indication for surgery and stabilization, based on the diagnostics applied and the time point assessed (pre- or intra-operatively), was analyzed, including the applied cutoff criteria.
- **Results:** Ten out of 4190 studies, comprising 317 acute ligamentous syndesmotic injuries, met the inclusion criteria. Seven studies facilitated one of the three different classification systems (Calder, West Point, or Sikka classification). Eight studies based their indication for surgery on a combination of clinical and radiographic examinations and two on radiographs only. The most applied clinical tests were the external rotation stress test and squeeze test. The most common radiologic diagnostics were plain radiographs and MRI. Intraoperatively, instability was verified most commonly using arthroscopy.
- **Conclusion:** Current classifications and diagnostics for syndesmotic injuries are heterogeneous, often cannot be attributed to the ligaments injured. An evidence-based diagnostic algorithm based on noninvasive diagnostics and an anatomy-based classification for acute syndesmotic instability is presented.

Keywords: syndesmosis; diagnosis; classification

## Introduction

Syndesmotic injuries occur in 20% of ankle fracture cases and in approximately 17% of all ankle sprains (1, 2, 3, 4). Isolated syndesmotic injuries are referred to as high ankle sprains. These figures rise to up to 30% in high-impact sports (5). Consequently, orthopedic surgeons are frequently encountered with syndesmotic injuries and must rate their stability.

The syndesmotic complex comprises of three major ligaments, the anterior-inferior tibiofibular ligament (AiTFL), the interosseous ligament (IOL), and the posterior-inferior tibiofibular ligament (PiTFL) (Fig. 1A) (6). It resembles a three-point fixation of the fibula to the tibia ensuring bony mortise stability (Fig. 1B) (7). The PiTFL accounts for about 40–45%, the AiTFL for 35% and the IOL for about 20–25% of the stability of the distal tibiofibular joint (DTFJ) (8). The most common injury mechanism is external rotation in dorsiflexion of the foot.

The syndesmotic complex most often ruptures from anterior to posterior. Biomechanically, an isolated rupture of the AiTFL leads to an increased anterior-to-posterior translation of the fibula, while a rupture of the AiTFL and IOL additionally results in a rotational instability. Only a complete rupture of all three ligaments (AiTFL, IOL, and PiTFL) causes a multiplanar instability of the DTFJ and leads to a frank diastasis (9).

The diagnosis and classification of two-ligament (AiTFL and IOL ruptures) and multiplanar instabilities (AiTFL, IOL, and PiTFL ruptures) remain a challenge (1, 10). Various clinical tests and diagnostics have been proposed, ranging from plain radiographs, MRI, to different stress tests. A similar number of varying classification systems have been published, using different combinations of the clinical tests and diagnostics. Yet, to this day, we are missing a uniform diagnostic algorithm and classification system for syndesmotic injuries. An untreated, unstable syndesmotic injury will significantly change the tibiotalar contact area and contact pressure (11), which again result in chronic instability, poor functional outcome,

and posttraumatic arthritis (12, 13). Considering these eventually irreversible consequences, it becomes apparent that we must agree on an evidence-based diagnostic algorithm and classification system.

The authors are only aware of one systematic review on the classification and diagnosis. This was published 7 years ago as a consensus statement by the ESSKA-AFAS (which stands for European Society for Sports Traumatology, Knee Surgery and Arthroscopy – Ankle and Foot Associates) (14). They predominantly focused on the combination of syndesmotic and deltoid injuries. Still, one has to be aware that the syndesmotic complex stabilizes the bony ankle mortise, i.e. the fibula to the tibia, and the deltoid ligament complex the medial ankle. Thus, for isolated syndesmotic injuries, a uniform classification and diagnostic standards, including cutoff values, is still lacking.

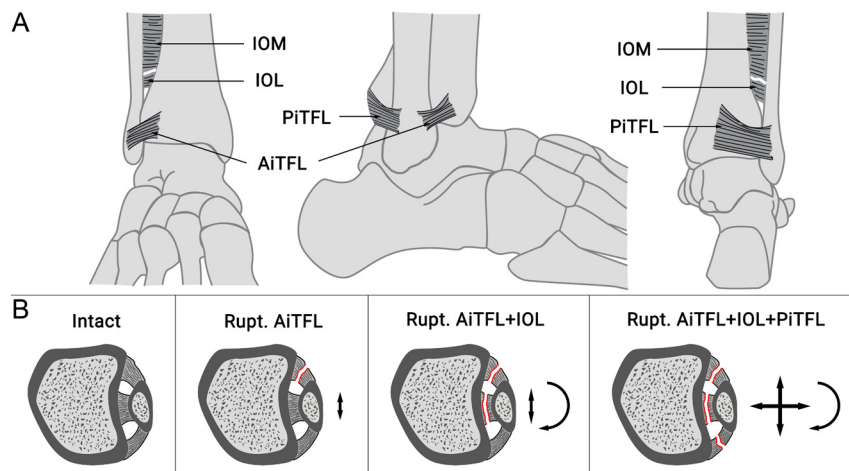
The aim of the current study was to conduct a systematic review on the classification systems and diagnostics applied to grade and diagnose syndesmotic instability in studies reporting the outcome of surgically treated acute, isolated syndesmotic injuries. The applied classification systems and diagnostics were discussed with current literature and a best evidence diagnostic approach was proposed.

## Materials and methods

The systematic review was conducted according to the Preferred Reporting Items for Systematic Reviews and Meta-Analyses (PRISMA) guidelines (15). The study was *a priori* registered at Prospero (CRD42022352940).

### Search strategy

Medline (PubMed), Scopus, Cochrane Central Register of Controlled Trials (aka CENTRAL), and Embase were searched from inception to June 5, 2022. The review question was framed according to the Population,



**Figure 1**

Schematic illustration of the syndesmotic complex (A) and the increase of fibula range of motion with stepwise rupture of the syndesmotic complex (B). AiTFL, anterior-inferior tibiofibular ligament; IOL, interosseous ligament; PiTFL, posterior-inferior tibiofibular ligament.

**Table 1** PICOS criteria defining the inclusion and exclusion criteria.

Population	<ul style="list-style-type: none"> <li>Adult patients (<math>\geq 19</math> years) who had suffered an acute (<math>&lt; 6</math> weeks), unstable syndesmotic injury</li> <li>Syndesmotic injury was defined as a ligamentous or bony avulsion injury (AiTFL or PiTFL) to the syndesmosis</li> <li>Unstable was not further specified but must be stated by the authors</li> </ul>
Intervention	Surgical treatment, independent of the treatment strategy chosen.
Comparison	n.a.
Outcomes	Any objective outcome, including imaging, PROMs, VAS, and range of motion
Study	Clinical studies. No restriction per the type of study unless they included at least six patients.

Intervention, Comparison, Outcomes and Study (PICOS) criteria (Table 1). The search strategy was built upon the principal strategies of Syndesmosis AND Surgery. The entire search strategy is presented in Supplementary 1 (see the section on [supplementary materials](#) given at the end of this article).

A grey literature search for conference proceedings was performed in Scopus and EMBASE and a general search in OpenGrey (<http://www.opengrey.eu>). In addition, all references of the studies included and systematic reviews identified were hand reviewed to find studies not found through the generic electronic search.

## Study selection and data extraction

Each database was searched separately, and the resulting datasets exported to Endnote™ (version 20.1; Clarivate). After removal of duplicates, the final dataset was exported to Covidence™ (Melbourne, Australia). The complete screening (title/abstract, full text) and data extraction process was conducted by two independent reviewers (FTS, SFB) and conflicts were discussed with a third reviewer (HP).

Data extraction was based on standardized data extraction sheets in Excel (version 16, Microsoft, Redmond, WA, USA), including level of evidence, study details, general demographics (number of patients, lost to follow-up, age, sex, etc.), injury defining information (diagnostic algorithm, classification system, and distribution of injuries), surgical treatment (closed, open, arthroscopically assisted), type of fixation, associated injuries such as intra-articular (i.a.) pathologies, postoperative treatment protocol, follow-up time, complications, and outcome.

## Quality assessment

Quality assessment was again conducted by two authors independently (SFB, FTS). According to the Joanna Briggs Institute (JBI) critical appraisal checklists for the various study types (16), the methodological quality of the included studies was evaluated. The JBI critical assessment checklist for cohort studies comprises of eleven items, and for case series of ten items. A JBI score  $> 70\%$  is considered good, medium if  $50\text{--}70\%$ , and poor for scores  $< 50\%$ .

## Data analysis

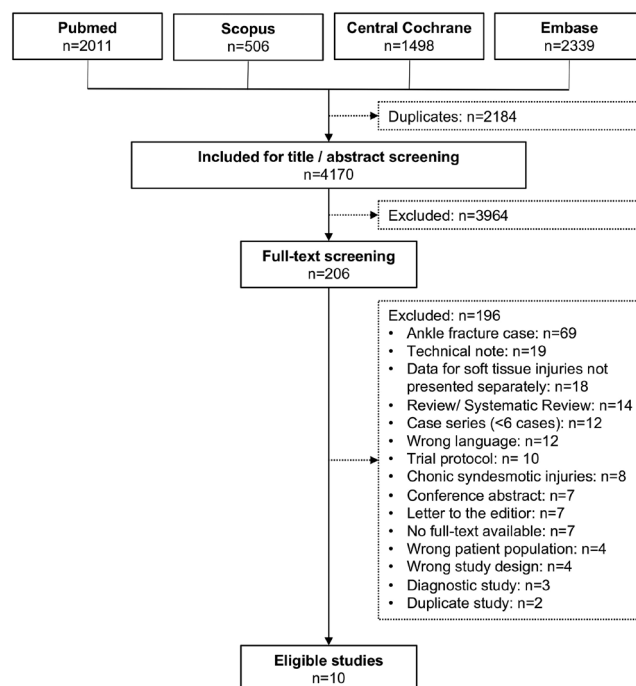
First, all classifications used in the eligible papers were identified and illustrated according to the individual syndesmotic structure injured or ruptured (AiTFL, IOL, PiTFL). Second, the indication for surgery and stabilization, based on the diagnostics applied and the time point assessed (pre- or intraoperatively), were analyzed, including the applied cutoff criteria.

## Statistical analysis

Due to the great heterogeneity of the studies available, the data analysis was conducted descriptively only. The data shown are given as mean  $\pm$  s.d.

## Results

Figure 2 depicts the study selection process. A total of 4190 studies were screened for title and abstract and

**Figure 2**

Study selection flowchart according to the PRISMA guidelines.

206 for full text. Eighteen studies included combined patient cohorts with ligamentous and fracture cases but did not present the results individually. All corresponding authors but one (contact details not available (17)) were contacted to provide the data for ligamentous and fracture cases separately. Only Cherney *et al.* (18) replied, stating that only one patient had a purely ligamentous injury. Consequently, all 18 studies had to be excluded. Finally, ten studies (19, 20, 21, 22, 23, 24, 25, 26, 27, 28), comprising 317 acute ligamentous syndesmotic injuries, were eligible for further analyses.

For the study by Kent *et al.* (24) only the study arm on acute injuries was included. The overall study quality per the JBI score was good ( $82 \pm 14\%$ ; case series:  $85 \pm 14\%$ ; cohort studies:  $69 \pm 5\%$ ). The mean patient age within the included studies was  $27 \pm 6$  years,  $19 \pm 21\%$  of the included patients were female and the mean follow-up time was  $32 \pm 15$  months.

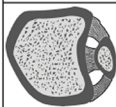
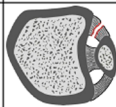
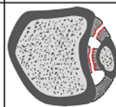
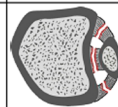
Supplementary Table 1 depicts an overview over the included studies.

## Classification systems

An illustration of the classification systems used in the studies included is depicted in Fig. 3. Seven out of the ten studies facilitated one of the following classification systems: Calder classification ( $n=4$ ) (19, 21, 24, 25), West Point classification ( $n=2$ ) (23, 28), and Sikka classification ( $n=1$ ) (26). The remaining three studies simply classified the injuries into stable or unstable (20, 22, 27).

## Indication for surgery and stabilization

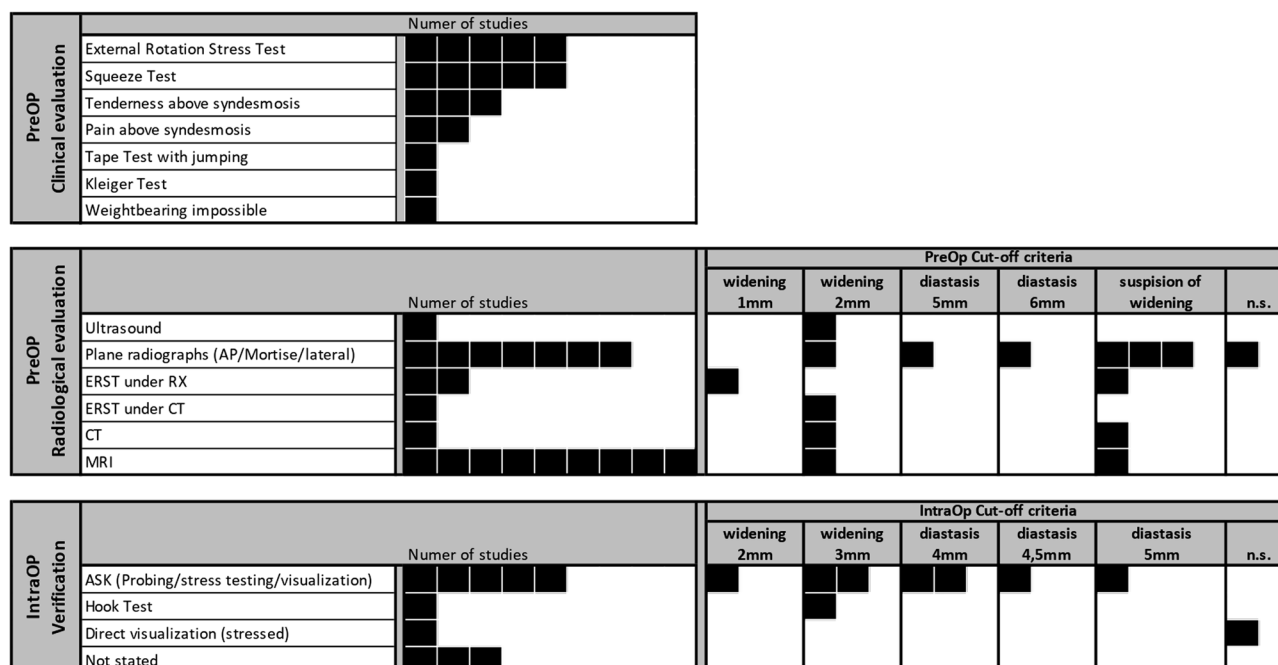
The diagnostics used to set the indication for surgery (preoperative) and stabilization (intraoperative) are depicted in Fig. 4. Overall, eight studies based their

		Intact	Rupt. AITFL	Rupt. AITFL + IOL	Rupt. AITFL + IOL + PITFL		
							
Classification	Publication					Deltoid	
Classifications identified in Systematic Review	West Point Classification	Gerber et al. 1998	Grade I: Squeeze OR ERST, RX.: neg. Grade II: Squeeze AND ERST, RX.: neg.			Grade III Squeeze AND ERST RX.: Mortis widening	No
	Sikka Classification	Sikka et al. 2012	not stated	Grade I MRI	Grade II MRI	Grade III MRI	Yes
	Calder Classification*	Calder et al. 2016	Grade I Squeeze OR ERST RX.: neg.	Grade IIA ERST pos. / Squeeze neg. MRI: Deltoid intact	Grade IIB ERST AND Squeeze pos. ± MRI Deltoid injury	Grade III ERST AND Squeeze pos. RX.: Mortise widening	Yes
Additional Classifications included in the ESSKA-AFAS consensus guidelines	Edwards and DeLee Classification	Edwards and DeLee 1984	not stated	Ankle sprain vs. Latent Diastasis (can not be attributed to an anatomical classification)		Frank Diastasis RX: Mortis widening	Yes
	Kelikian and Kelikian Classification	Kelikian H and Kelikian A. 1985	not stated	Type I: Rupt. anterior components of syndesmosis Type II: Rupt. all syndesmotic ligaments ± rupt. deltoid ligament ± fract. med. mall. Type III: Rupt. IOM, metaphyseal fibula fracture, physial tibia fracture, syndesmosis intact			Yes
	Marymont Classification	Marymont et al. 1986	Grade 0 Stress RX: neg. Bone scintigraphy: neg.	Grade I: Stress RX: neg.; Bone scintigraphy: pos. Grade II: Stress RX: pos. <1mm widening ankle Mortis; Bone scintigraphy: pos. Grade III: Stress RX: pos. >1mm widening ankle Mortis; Bone scintigraphy: pos.		not classified	No
	Porter Classification	Porter et al. 2009	not stated	Grade I: AITFL, IOL, ant. deltoid ligament Grade II: Tear significant portion of syndesmosis, anterior and deep deltoid ligament Grade III: Extensive disruption of syndesmosis, complete disruption deltoid ligament			Yes
	Massobrio Classification	Massobrio et al. 2011	Grade 0: Normal tibiofibular overlap Grade I: Overlap equal or exceeding 50% Grade II: Overlap lower than 50% Grade III: No overlap at all				No
Further classifications	Press Classification	Presst et al. 2009	Grade I Stable exam RX.: neg.; ERST neg.		Grade II Mild laxity RX: ERST 0-1mm laxity	Grade III Unstable exam RX: Mortis widening, ERST unstable	No

\* Not included in the ESSKA-AFAS consensus guideline classifications

**Figure 3**

Illustration of the classification systems facilitated in the herein identified studies, included in the ESSKA-AFAS consensus guidelines (14), and other classification systems: \*Not included in the ESSKA-AFAS consensus guideline classifications. AITFL, anterior-inferior tibiofibular ligament; ERST, external rotation stress test; IOL, interosseous ligament; neg., negative; PITFL, posterior-inferior tibiofibular ligament; pos., positive; RX, x-ray.

**Figure 4**

Overview of the diagnostic tests used in the included studies. Each black square resembles a single study in which this test was used within the authors' diagnostic algorithm. AP, anterior–posterior; CT, computed tomography; ERST, external rotation stress test; IntraOP, intraoperative; n.s., not specified; PreOP, preoperative; RX, x-ray.

indication for surgery (preoperative) on a combination of clinical and radiographic examinations (19, 21, 22, 23, 24, 25, 26, 27). The remaining two studies based their indication for surgery solely on radiographs (20, 28). The most applied clinical tests were the external rotation stress test (ERST) ( $n=5$ ; (19, 21, 23, 24, 25)) and squeeze test ( $n=5$ ; (19, 21, 22, 23, 24)), and the most common radiologic diagnostics MRI ( $n=9$ ; (19, 20, 21, 22, 23, 24, 25, 26, 27)) and plane radiographs ( $n=7$ ; (19, 20, 22, 23, 26, 27, 28)). The most frequently applied cutoff criteria, independent of the actual radiologic tool, were 2 mm ( $n=5$ ; (23, 25, 27)) and 'suspicion of widening' ( $n=6$ ; (19, 26, 27)).

Seven studies verified syndesmotic instability intraoperatively (19, 20, 21, 23, 24, 25, 27). This was most often done by arthroscopy ( $n=5$ ) (19, 21, 24, 25, 27) with cutoff values in the stressed state ranging from 2 mm (27) to 4.5 mm (19).

## Discussion

The aim of this systematic review was to identify the classification systems and diagnostics applied to grade and diagnose syndesmotic instability in studies reporting on the outcome of surgically treated acute, isolated syndesmotic injuries.

The most often used classification systems were the Calder, West Point, or Sikka classification. The most

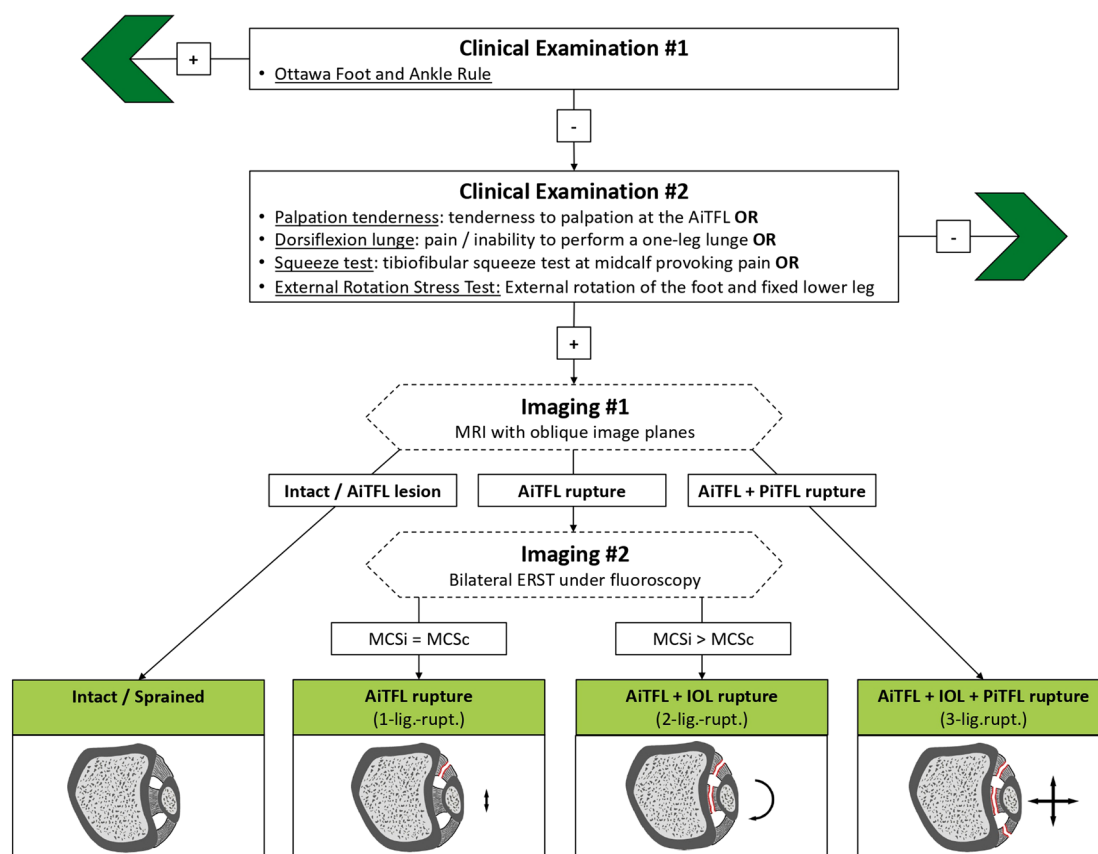
applied clinical tests were the ERST and squeeze test. The most common radiological diagnostics were plain radiographs and MRI. Arthroscopy was most used to verify syndesmotic instability intraoperatively. The results highlight the great heterogeneity in the classification systems used and diagnostics applied for acute, isolated syndesmotic injuries.

Figure 3 combines the clinically applied classification systems identified in the systematic literature review (1, 19, 29), reported in the ESSKA-AFAS expert panel consensus guideline (14), and a further classification identified during the literature review for this study (30). Only classification systems applicable preoperatively were included. Intraoperative classification systems, i.e. based on a hook test or arthroscopy, were not included. The different classification systems were grouped, whenever possible, per the specific syndesmotic ligaments injured. Five studies did not clearly state on the ligaments injured and could therefore not be grouped (1, 9, 31, 32, 33). This overview highlights the enormous heterogeneity we are currently facing when classifying syndesmotic injuries. This heterogeneity includes varying terminology, missing the differentiation between stable and subtle unstable injuries, and an incorporation of deltoid ligament injuries into the classification systems. Although most classification systems used grades, most commonly I through III (1, 19, 29, 30, 31, 32, 33, 34), these grades either cannot be clearly attributed to the individual syndesmotic ligaments



## Acute ligamentous syndesmotic injury

### Diagnostic and classification algorithm



**Figure 5**

Overview of the MUM diagnostic flowchart for the diagnosis of isolated ligamentous injuries to the syndesmosis. AiTFL, anterior–inferior tibiofibular ligament; ERST, external rotation stress test; IOL, interosseous ligament; lig., ligament; MCS, medial clear space; PiTFL, posterior–inferior tibiofibular ligament.

injured or refer to different states of syndesmotic instability which further increases the confusion (Fig. 3). A clear differentiation between a one-ligament rupture (AiTFL) and a two-ligament rupture (AiTFL + IOL) is only provided in three classification systems (19, 29, 30). Yet this differentiation is crucial, as it has considerable implications for the further treatment, i.e. nonoperative vs operative (19). Finally, five (9, 19, 29, 31, 34) out of the nine classification systems identified incorporate injuries to the deltoid ligament complex into their classification system. In 2016, the ESSKA-AFAS expert

panel published a consensus and guideline paper entitled ‘Classification and diagnosis of acute isolated syndesmotic injuries’ (14). They concluded that the injury to the deltoid ligament is the predominant differentiator between a stable and a latent unstable syndesmotic injury. This is remarkable, as the role of the deltoid ligament complex on the stability of the distal tibiofibular joint is not yet clear and currently intensively debated. Furthermore, various studies have highlighted the essential role of the IOL for distal tibiofibular joint stability (35, 36, 37, 38, 39, 40, 41).

Therefore, the authors believe that any classification system for syndesmotic injuries should solely focus on the syndesmotic complex and the individual ligaments injured. A consistent and reproducible classification system is needed to ensure a comparability between studies and for the development of evidence-based treatment guidelines.

The second aim of the current systematic review was to identify the most commonly used preoperative diagnostics to diagnose syndesmotic instability, i.e. differentiate between stable and unstable syndesmotic injuries. The most commonly applied diagnostics were MRI and plain radiographs. Interestingly, the external rotation stress test under fluoroscopy was facilitated only in two studies preoperatively (27, 28) and in none intraoperatively. Furthermore, only two of the classification systems identified recommended to apply the ERST under fluoroscopy (Fig. 3) (30, 32). This was surprising, as this test is the working horse to assess syndesmotic stability in ankle fracture cases (42, 43, 44). Moreover, a just recently published systematic review assessed the value of the ERST under fluoroscopy to detect subtle syndesmotic instability (45). Based on the ERST under fluoroscopy, the MCS was capable of differentiating between intact, two-ligament (AiTFL + IOL), three-ligament (AiTFL + IOL + PiTFL), and three-ligament + deltoid ruptures. The ERST under fluoroscopy has several advantages over MRI or arthroscopy: It is a dynamic examination and can be applied both in the outpatient clinic 5–7 days after injury without additional anesthesia and intraoperatively. It can be conducted bilaterally and therefore does not rely on predefined cutoff values, as arthroscopic probing, for example, does; thus, the healthy, uninjured side can serve as a reference. Finally, it is widely available and cost-efficient.

Based on these considerations, the authors have defined a best-evidence diagnostic algorithm for acute, isolated syndesmotic injuries (Fig. 5). ‘Acute’ was defined as, in accordance with the ESSKA-AFAS expert panel, within the first 21 days (14). The clinical examination should include the Ottawa foot and ankle rules (46) and syndesmosis-specific tests. Yet, clinical tests can only indicate a syndesmotic injury but not clearly differentiate between stable and unstable syndesmotic injuries (14, 47, 48, 49). In case there is the clinical suspicion for a syndesmotic lesion, an MRI should be obtained. MRI allows to clearly identify an intact AiTFL (stable) or a complete rupture of the AiTFL and PiTFL (unstable). In case the AiTFL is injured/ruptured but the PiTFL is intact, a bilateral ERST under fluoroscopy should be obtained. A widening of the MCS of the injured compared to the contralateral side, indicates an unstable (AiTFL + IOL rupture) syndesmotic injury. The subsequent injury should then be classified according to the specific syndesmotic ligaments injured. Additional injuries, such as injuries to the deltoid ligament complex, should be classified separately.

## Conclusion

Currently available classification systems for syndesmotic injuries are heterogeneous, often cannot clearly be attributed to the ligaments injured, and associate injuries to the syndesmotic and deltoid ligament complexes. Similarly, current studies on isolated, syndesmotic injuries use different and often insufficient diagnostics to diagnose syndesmotic instability. The classification system and diagnostic algorithm introduced in this paper aim at providing a precise terminology and a noninvasive, best diagnostic approach to identify acute syndesmotic instability.

### Supplementary materials

This is linked to the online version of the paper at <https://doi.org/10.1530/EOR-23-0097>.

### ICMJE Conflict of Interest Statement

The authors declare that there is no conflict of interest that could be perceived as prejudicing the impartiality of the study reported.

### Funding Statement

The authors received no financial or material support for the research, authorship, and/or publication of this article.

### Author contribution statement

FTS reviewed the literature, wrote and edited the manuscript, contributed to data synthesis and assisted in illustration. WB supervised the study and reviewed the manuscript. HP supervised the study, reviewed the manuscript, and was responsible for the project administration. SFB conceptualized the study idea and the methodology, reviewed the literature, wrote the manuscript, designed the figures, and contributed to data synthesis.

## References

- Gerber JP, Williams GN, Scoville CR, Arciero RA & Taylor DC. Persistent disability associated with ankle sprains: a prospective examination of an athletic population. *Foot and Ankle International* 1998 **19** 653–660. (<https://doi.org/10.1177/107110079801901002>)
- Hopkinson WJ, St Pierre P, Ryan JB & Wheeler JH. Syndesmosis sprains of the ankle. *Foot and Ankle* 1990 **10** 325–330. (<https://doi.org/10.1177/107110079001000607>)
- Court-Brown CM, McBurnie J & Wilson G. Adult ankle fractures—an increasing problem? *Acta Orthopaedica Scandinavica* 1998 **69** 43–47. (<https://doi.org/10.3109/17453679809002355>)
- Lindsjo U. Operative treatment of ankle fractures. *Acta Orthopaedica Scandinavica* 1981 **189** 1–131. (<https://doi.org/10.3109/ort.1981.52.suppl-189.01>)
- Mulcahey MK, Bernhardtson AS, Murphy CP, Chang A, Zajac T, Sanchez G, Sanchez A, Whalen JM, Price MD, Clanton TO, *et al.* The epidemiology of ankle injuries identified at the National Football League combine, 2009–2015. *Orthopaedic Journal of Sports Medicine* 2018 **6** 2325967118786227. (<https://doi.org/10.1177/2325967118786227>)

- 6 Yammine K, Jalloul M & Assi C. Distal tibiofibular syndesmosis: a meta-analysis of cadaveric studies. *Morphologie: Bulletin de l'Association des Anatomistes* 2022 **106** 241–251. (<https://doi.org/10.1016/j.morpho.2021.10.004>)
- 7 Williams BT, Ahrberg AB, Goldsmith MT, Campbell KJ, Shirley L, Wijdicks CA, LaPrade RF & Clanton TO. Ankle syndesmosis: a qualitative and quantitative anatomic analysis. *American Journal of Sports Medicine* 2015 **43** 88–97. (<https://doi.org/10.1177/0363546514554911>)
- 8 Ogilvie-Harris DJ, Reed SC & Hedman TP. Disruption of the ankle syndesmosis: biomechanical study of the ligamentous restraints. *Arthroscopy* 1994 **10** 558–560. ([https://doi.org/10.1016/s0749-8063\(05\)80014-3](https://doi.org/10.1016/s0749-8063(05)80014-3))
- 9 Edwards GS, Jr & DeLee JC. Ankle diastasis without fracture. *Foot and Ankle* 1984 **4** 305–312. (<https://doi.org/10.1177/107110078400400606>)
- 10 Chun DI, Cho JH, Min TH, Park SY, Kim KH, Kim JH & Won SH. Diagnostic accuracy of radiologic methods for ankle syndesmosis injury: a systematic review and meta-analysis. *Journal of Clinical Medicine* 2019 **8**. (<https://doi.org/10.3390/jcm8070968>)
- 11 Burns WC, 2nd, Prakash K, Adelaar R, Beaudoin A & Krause W. Tibiotalar joint dynamics: indications for the syndesmosis screw—a cadaver study. *Foot and Ankle* 1993 **14** 153–158. (<https://doi.org/10.1177/107110079301400308>)
- 12 Ray R, Koohnejad N, Clement ND & Keenan GF. Ankle fractures with syndesmosis stabilisation are associated with a high rate of secondary osteoarthritis. *Foot and Ankle Surgery* 2019 **25** 180–185. (<https://doi.org/10.1016/j.fas.2017.10.005>)
- 13 Saltzman CL, Salamon ML, Blanchard GM, Huff T, Hayes A, Buckwalter JA & Amendola A. Epidemiology of ankle arthritis: report of a consecutive series of 639 patients from a tertiary orthopaedic center. *Iowa Orthopaedic Journal* 2005 **25** 44–46.
- 14 van Dijk CN, Longo UG, Loppini M, Florio P, Maltese L, Ciuffreda M & Denaro V. Classification and diagnosis of acute isolated syndesmosis injuries: ESSKA-AFAS consensus and guidelines. *Knee Surgery, Sports Traumatology, Arthroscopy* 2016 **24** 1200–1216. (<https://doi.org/10.1007/s00167-015-3942-8>)
- 15 Page MJ, McKenzie JE, Bossuyt PM, Boutron I, Hoffmann TC, Mulrow CD, Shamseer L, Tetzlaff JM, Akl EA, Brennan SE, et al. The PRISMA 2020 statement: an updated guideline for reporting systematic reviews. *BMJ* 2021 **372** n71. (<https://doi.org/10.1136/bmj.n71>)
- 16 Moola S, Munn Z, Tufanaru C, Aromataris E, Sears K, Sfetcu R, Currie M, Lisy K, Qureshi R, Mattis P, et al. Chapter 7: Systematic reviews of etiology and risk. In *JBIM Manual for Evidence Synthesis*. E Aromataris & Z Munn Eds. JBI 2020. (<https://doi.org/10.46658/JBIMES-20-08>)
- 17 Henkemeyer H, Burri C & Bargon G. Results of surgical management of 42 syndesmosis injuries. *Helvetica Chirurgica Acta* 1976 **43** 485–486.
- 18 Cherney SM, Cosgrove CT, Spraggs-Hughes AG, McAndrew CM, Ricci WM & Gardner MJ. Functional outcomes of syndesmosis injuries based on objective reduction accuracy at a minimum 1-year follow-up. *Journal of Orthopaedic Trauma* 2018 **32** 43–51. (<https://doi.org/10.1097/BOT.0000000000001000>)
- 19 Calder JD, Bamford R, Petrie A & McCollum GA. Stable versus unstable Grade II high ankle sprains: a prospective study predicting the need for surgical stabilization and time to return to sports. *Arthroscopy* 2016 **32** 634–642. (<https://doi.org/10.1016/j.arthro.2015.10.003>)
- 20 Chen KH, Chen CH, Huang YM, Lee HH & Tsuang YH. Injury mechanism affects the stability of suture-button syndesmosis fixation. *Journal of Orthopaedic Surgery and Research* 2020 **15** 599. (<https://doi.org/10.1186/s13018-020-02141-3>)
- 21 D'Hooghe P, Grassi A, Alkhelaifi K, Calder J, Baltes TPA, Zaffagnini S & Ekstrand J. Return to play after surgery for isolated unstable syndesmosis ankle injuries (West Point grade IIB and III) in 110 male professional football players: a retrospective cohort study. *British Journal of Sports Medicine* 2020 **54** 1168–1173. (<https://doi.org/10.1136/bjsports-2018-100298>)
- 22 Förschner PF, Beitzel K, Imhoff AB, Buchmann S, Feuerriegel G, Hofmann F, Karampinos DC, Jungmann P & Pogorzelski J. Five-year outcomes after treatment for acute instability of the tibiofibular syndesmosis using a suture-button fixation system. *Orthopaedic Journal of Sports Medicine* 2017 **5** 2325967117702854. (<https://doi.org/10.1177/2325967117702854>)
- 23 Harris NJ, Nicholson G & Pountos I. Anatomical reconstruction of the anterior inferior tibiofibular ligament in elite athletes using InternalBrace suture tape. *Bone and Joint Journal* 2022 **104-B** 68–75. (<https://doi.org/10.1302/0301-620X.104B1.BJJ-2021-0542.R2>)
- 24 Kent S, Yeo G, Marsland D, Randell M, Forster B, Lutz M & Okano S. Delayed stabilisation of dynamically unstable syndesmosis injuries results in worse functional outcomes. *Knee Surgery, Sports Traumatology, Arthroscopy* 2020 **28** 3347–3353. (<https://doi.org/10.1007/s00167-020-05962-1>)
- 25 Kim JS & Shin HS. Suture anchor augmentation for acute unstable isolated ankle syndesmosis disruption in athletes. *Foot and Ankle International* 2021 **42** 1130–1137. (<https://doi.org/10.1177/10711007211015188>)
- 26 Latham AJ, Goodwin PC, Stirling B & Budgen A. Ankle syndesmosis repair and rehabilitation in professional rugby league players: a case series report. *BMJ Open Sport and Exercise Medicine* 2017 **3** e000175. (<https://doi.org/10.1136/bmjsem-2016-000175>)
- 27 Nishikawa DRC, Saito GH, de Oliveira Junior AS, Mendes AAM, Devito LP & Prado MP. Clinical outcomes of isolated acute instability of the syndesmosis treated with arthroscopy and percutaneous suture-button fixation. *Archives of Orthopaedic and Trauma Surgery* 2021 **141** 1567–1574. (<https://doi.org/10.1007/s00402-021-03813-3>)
- 28 Taylor DC, Tenuta JJ, Uhorchak JM & Arciero RA. Aggressive surgical treatment and early return to sports in athletes with grade III syndesmosis sprains. *American Journal of Sports Medicine* 2007 **35** 1833–1838. (<https://doi.org/10.1177/0363546507304666>)
- 29 Sikka RS, Fetzer GB, Sugarman E, Wright RW, Fritts H, Boyd JL & Fischer DA. Correlating MRI findings with disability in syndesmosis sprains of NFL players. *Foot and Ankle International* 2012 **33** 371–378. (<https://doi.org/10.3113/FAI.2012.0371>)
- 30 Press CM, Gupta A & Hutchinson MR. Management of ankle syndesmosis injuries in the athlete. *Current Sports Medicine Reports* 2009 **8** 228–233. (<https://doi.org/10.1249/JSR.0b013e3181b7ec0c>)
- 31 Kelikian H & Kelikian AS *Disorders of the Ankle*. Philadelphia: Saunders 1985.
- 32 Marymont JV, Lynch MA & Henning CE. Acute ligamentous diastasis of the ankle without fracture. Evaluation by radionuclide imaging. *American Journal of Sports Medicine* 1986 **14** 407–409. (<https://doi.org/10.1177/036354658601400514>)
- 33 Massobrio M, Antonietti G, Albanese P & Necci F. Operative treatment of tibiofibular diastasis: a comparative study between transfixation screw and reabsorbable cerclage. Preliminary result. *Clinica Terapeutica* 2011 **162** e161–e167.
- 34 Porter DA. Evaluation and treatment of ankle syndesmosis injuries. *Instructional Course Lectures* 2009 **58** 575–581.
- 35 Zwipp H *Chirurgie Des Fußes*. Vienna: Springer-Verlag 1994.



- 36 Close JR. Some applications of the functional anatomy of the ankle joint. *Journal of Bone and Joint Surgery. American Volume* 1956 **38-a** 761–781.
- 37 Outland T. Sprains and separations of the inferior tibiofibular joint without important fracture. *American Journal of Surgery* 1943 **59** 320–329. ([https://doi.org/10.1016/S0002-9610\(43\)90419-2](https://doi.org/10.1016/S0002-9610(43)90419-2))
- 38 Hoefnagels EM, Waites MD, Wing ID, Belkoff SM & Swierstra BA. Biomechanical comparison of the interosseous tibiofibular ligament and the anterior tibiofibular ligament. *Foot and Ankle International* 2007 **28** 602–604. (<https://doi.org/10.3113/FAI.2007.0602>)
- 39 Rammelt S, Zwipp H & Grass R. Injuries to the distal tibiofibular syndesmosis: an evidence-based approach to acute and chronic lesions. *Foot and Ankle Clinics* 2008 **13** 611–633. (<https://doi.org/10.1016/j.fcl.2008.08.001>)
- 40 McCullough CJ & Burge PD. Rotatory stability of the load-bearing ankle. An experimental study. *Journal of Bone and Joint Surgery* 1980 **62-B** 460–464.
- 41 Snedden MH & Shea JP. Diastasis with low distal fibula fractures: an anatomic rationale. *Clinical Orthopaedics and Related Research* 2001 **382** 197–205. (<https://doi.org/10.1097/00003086-200101000-00027>)
- 42 Purcell KF, Bergin PF, Russell GV, Graves ML, Jones LC & Spitler CA. Tibial shaft and Pilon fractures with associated syndesmotom injury: a matched cohort assessment. *Journal of Orthopaedic Trauma* 2022 **36** 157–162. (<https://doi.org/10.1097/BOT.0000000000002252>)
- 43 Kellam PJ, Dekeyser GJ, Haller JM, Rothberg DL, Higgins TF & Marchand LS. Predicting syndesmotom injury in OTA/AO 44-B2.1 (Danis-Weber B) fractures. *Journal of Orthopaedic Trauma* 2021 **35** 473–478. (<https://doi.org/10.1097/BOT.0000000000002052>)
- 44 Hunt KJ, Phisitkul P, Pirolo J & Amendola A. High ankle sprains and syndesmotom injuries in athletes. *Journal of the American Academy of Orthopaedic Surgeons* 2015 **23** 661–673. (<https://doi.org/10.5435/JAAOS-D-13-00135>)
- 45 Spindler FT, Herterich V, Holzapfel BM, Bocker W, Polzer H & Baumbach SF. A systematic review and meta-analysis on the value of the external rotation stress test under fluoroscopy to detect syndesmotom injuries. *EFORT Open Reviews* 2022 **7** 671–679. (<https://doi.org/10.1530/EOR-22-0037>)
- 46 Stiell IG, Greenberg GH, McKnight RD, Nair RC, McDowell I, Reardon M, Stewart JP & Maloney J. Decision rules for the use of radiography in acute ankle injuries. Refinement and prospective validation. *JAMA* 1993 **269** 1127–1132. (<https://doi.org/10.1001/jama.269.9.1127>)
- 47 Netterstrom-Wedin F & Bleakley C. Diagnostic accuracy of clinical tests assessing ligamentous injury of the ankle syndesmosis: a systematic review with meta-analysis. *Physical Therapy in Sport* 2021 **49** 214–226. (<https://doi.org/10.1016/j.ptsp.2021.03.005>)
- 48 Sman AD, Hiller CE & Refshauge KM. Diagnostic accuracy of clinical tests for diagnosis of ankle syndesmosis injury: a systematic review. *British Journal of Sports Medicine* 2013 **47** 620–628. (<https://doi.org/10.1136/bjsports-2012-091702>)
- 49 Schwieterman B, Haas D, Columer K, Knupp D & Cook C. Diagnostic accuracy of physical examination tests of the ankle/foot complex: a systematic review. *International Journal of Sports Physical Therapy* 2013 **8** 416–426.